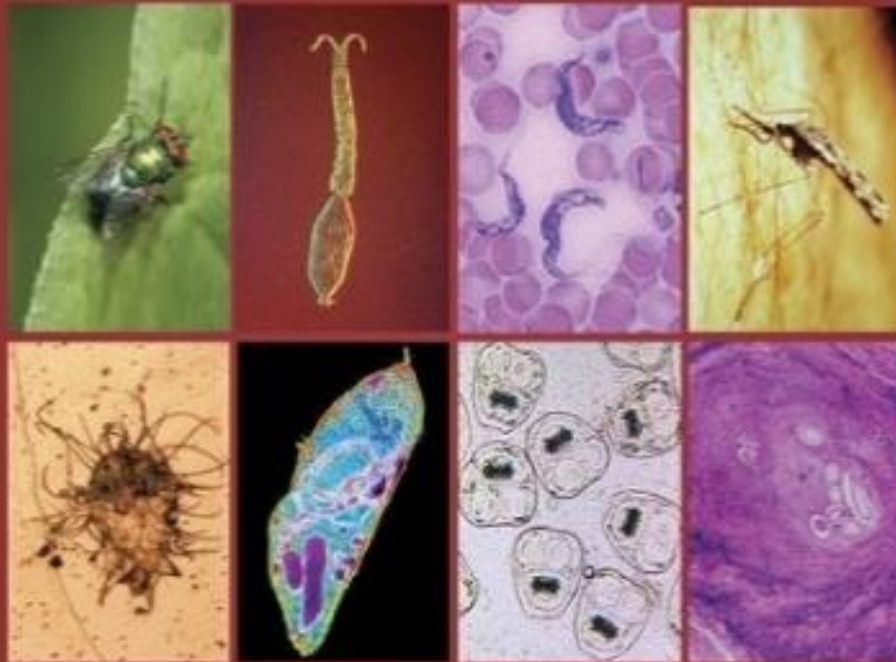



EGYPTIAN ACADEMIC JOURNAL OF  
**BIOLOGICAL SCIENCES**

**MEDICAL ENTOMOLOGY & PARASITOLOGY**


**E**



ISSN  
2090-0783

[WWW.EAJBS.EG.NET](http://WWW.EAJBS.EG.NET)

**Vol. 15 No. 1 (2023)**



## Demodex Mite Infections: About Two Cases of Demodicosis in Rosacea Associated Respectively with Recurrent Chalazion and Allergic Rhinitis in Dakar, Senegal

Khadim Diongue<sup>1,\*</sup>, Mamadou Alpha Diallo<sup>1</sup>, Mame Cheikh Seck<sup>1</sup>, Babacar Ndiaye<sup>2</sup>, Hadi Hakim<sup>3</sup>, Mouhamadou Ndiaye<sup>1</sup>, Aïda Sadikh Badiane<sup>1</sup> and Daouda Ndiaye<sup>1</sup>

<sup>1</sup> Laboratory of Parasitology and Mycology, Aristide Le Dantec University Hospital, Dakar 3001, Senegal.

<sup>2</sup> Laboratory of Medical Biology, Pasteur Institute, Dakar, Senegal.

<sup>3</sup> Cabinet de Dermatologie-Vénérologie, 70 rue Amadou Assane Ndoye, Dakar 22 103, Senegal.

\*E-mail : [khadimase@gmail.com](mailto:khadimase@gmail.com)

### ARTICLE INFO

#### Article History

Received:7/4/2023

Accepted:16/6/2023

Available:21/6/2023

#### Keywords:

Demodicosis;

*Demodex*

*folliculorum*;

Rosacea; Senegal.

### ABSTRACT

Demodicosis is an ectoparasitic disease caused by *Demodex* spp. Generally asymptomatic in healthy individuals, the incidence and the pathogenicity of *Demodex* mites are increased when the host presents facial skin diseases such as rosacea. In addition, rosacea is often diagnosed in light-skinned patients and is much less evoked in patients with darker skin - as in Sub-Saharan Africa - in whom it is probably underdiagnosed. Thus, we reported two cases of *D. folliculorum* infestation associated with rosacea in Dakar, Senegal. The first case was a 32-year-old woman with symmetrical erythema of the cheeks, formed by superficial papulopustular lesions, evoking rosacea-like demodicosis lasting for several weeks and associated with recurrent chalazion. The second case concerns a 40-year-old man with deep, embedded, and painful papulopustular lesions located on the cheeks, the peri-oral, and peri-auricular areas less than a month ago. He presented such lesions three months ago, and more than six months ago. The two patients were sent to the parasitology and mycology laboratory in Aristide Le Dantec University Hospital for parasitological analysis which revealed adult forms of *Demodex folliculorum* in large quantities, associated with eggs in the second case. Initiation of oral treatment with ivermectin and doxycycline tablets, combined with local treatment with metronidazole, for six weeks, led to the disappearance of the symptomatology for both two cases.

### INTRODUCTION

Demodicosis is an ectoparasitic disease caused by *Demodex* spp. which are saprophytic mites of the ocular adnexa. Among the hundred known species, two colonize humans: *D. folliculorum* and *D. brevis* (Aktaş Karabay and Aksu Çerman, 2020; Ben Hadj Salah *et al.*, 2020). In addition, Ben Hadj Salah *et al.*, (Ben Hadj Salah *et al.*, 2020) citing a meta-analysis by Chang and Huang (Chang and Huang, 2017) indicated that *D. folliculorum* was found with a higher frequency and density on skin samples in patients with rosacea than in controls. Although their pathogenicity has long been controversial, certain conditions could favor their proliferation, which would be involved in certain dermatoses as well as in certain inflammatory signs on the eyelid (Ben Hadj Salah *et al.*, 2020). Previously, several studies linked *D. folliculorum* to skin and follicles diseases such as rosacea, blepharitis, chalazion, perioral dermatitis, seborrheic dermatitis and acne vulgaris (Arlı *et al.*, 2019; Fromstein *et al.*, 2018; Huang *et al.*, 2022; Kubanov *et al.*, 2019).

Generally asymptomatic in healthy individuals, the incidence and the pathogenicity of *D. folliculorum* are increased when the host has a weakened immune system including smoking or alcoholism, high consumption of spicy foods, advanced age, stress, or has allergic skin diseases that disrupt the integrity of the skin (Arlı *et al.*, 2019). If these contributing factors are common and found everywhere in all categories of the population, on the other hand, rosacea, which most often affects light-skinned patients, would be much less frequent in darker-skinned patients in whom it is probably underdiagnosed (Paichitrojjana, 2022). Here, we reported two cases of *D. folliculorum* infestation associated with rosacea and recurrent chalazion and allergic rhinitis, respectively.

#### MATERIALS AND METHODS

This case series included two patients received at the laboratory of Parasitology and Mycology in Aristide Le Dantec University Hospital between June, 1<sup>st</sup> and July 15<sup>th</sup> 2022. All participants gave written informed consent. The study was carried out according to the principles expressed in the Declaration of Helsinki.

The physical examination of both patients was carried out by the same dermatologist. The patients' sociodemographic data including age, and sex, as well as clinical diagnosis, symptoms, other possible facial dermatoses,

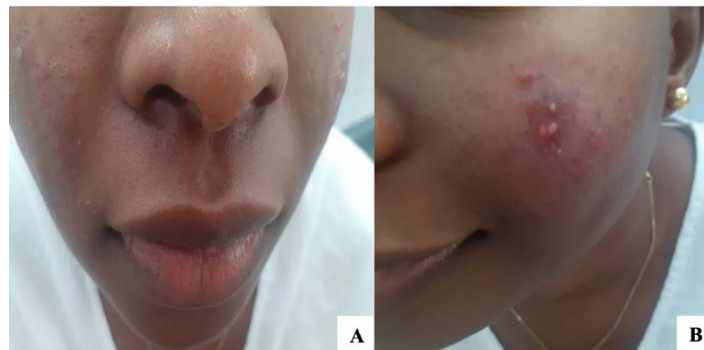and recent treatment for the facial condition were recorded.

For parasitological examination, the presence of *Demodex* mites was evaluated by direct microscopic examination (DME). Samples for mite examination were collected by scraping the erythematous lesions of the disease on the face on a Petri dish. Once the scales had been collected, transparent tape (Scotch<sup>®</sup>) was applied to the sampled area and then glued to a slide. The scales were then mounted in 20% potassium hydroxide (KOH). The both preparations were examined under a light microscope at  $\times 20$  then  $\times 40$  magnification.

#### RESULTS

##### Case 1:


This is a 32-year-old woman, external auditor, who consults a dermatologist for redness of the cheeks, associated with desquamation, evolving for several weeks. This erythrosis has increased since returning from a work trip to a country in the sub-region. The interrogation reveals a notion of stress during this work trip. On clinical examination, a regressing chalazion in the left eye is observed, and symmetrical erythema of the cheeks, formed by superficial papulopustular lesions, evoking rosacea-like (rosaceiform) demodicosis (Fig. 1). In addition, the patient reports that she has had chalazion repeatedly for nearly four years. The rest of the clinical examination is without abnormality. She takes no medication.



**Fig. 1:** Symmetrical rosacea-like demodicosis (A) with papulo-pustular lesions (B).

Thus, the was sent to the parasitology and mycology laboratory at Aristide Le Dantec University Hospital, Dakar (Senegal) for parasitological

analysis. Parasitological analysis of the scales collected by scraping the lesions revealed adult forms of *Demodex folliculorum* in large quantities (Fig. 2).



**Fig. 2:** Two specimens of *Demodex folliculorum* on the same microscopic field recognizable by their elongated posterior end (A, x400), and the whole body of the mite with striated posterior part and the anterior part bearing four pairs of legs (B, arrows, x400).

Initiation of oral treatment with ivermectin (Ivermectin Arrow<sup>®</sup>, 3 mg, tablet) at a dose of four tablets per day between meals (1 to 2 hours) for seven days, and doxycycline (Longamycin 200 mg, tablet) at a dose of half a tablet with a meal in the evening for 45 days, combined with local treatment with metronidazole (Rosex<sup>®</sup> 0.75% cream) with an application on the lesions in the evening, every day for six weeks, led to the disappearance of the symptomatology.

#### Case 2:

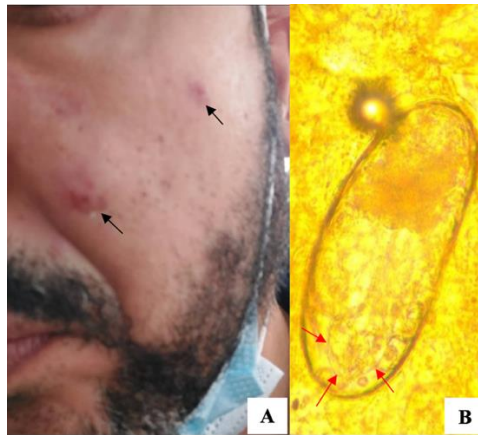This is a 40-year-old man of Turkish origin, recently in Senegal, who consults in dermatology for reddish and painful pimples on the face. These pimples appeared less than a month ago. During the interrogation, the patient reports having already had such pimples three months ago, and before (more than six months) when he lived in the south of France. Their appearance is often concomitant with allergic rhinitis, for which he had to take

medication, especially during the first episode. On clinical examination, we observe papulopustular lesions that were deep, embedded, and painful. The lesions located in particular on the cheeks, the perioral, and peri-auricular areas (Fig. 3A), also evoke granulomatous rosacea-like demodicosis. The rest of the clinical examination was unremarkable and the patient was not on any medication.

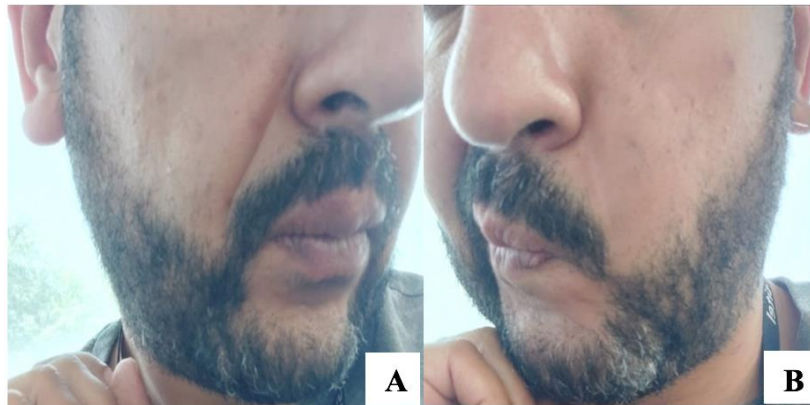Thus, he was also sent to the parasitology and mycology laboratory at Aristide Le Dantec University Hospital for parasitological analysis. Parasitological analysis as described in the above-revealed adult forms in large quantities, associated in this case with an egg of *Demodex folliculorum* (Fig. 3B).

Initiation of oral treatment associated with local treatment according to the same drug regimen as in the above led to a clinical recovery with the disappearance of the symptomatology (Fig. 4).





**Fig. 3:** Granulomatous-like rosacea demodicosis (A, black arrows), and embryonated egg of *Demodex folliculorum* showing an emerging larva (B, red arrows, x400).



**Fig. 4:** One-month test-of-cure showing clinical improvement under treatment for both cheeks (A and B).

### DISCUSSION

*Demodex* is the sole ectoparasite commensal on human skin (as a normal part of the flora) particularly on the pilosebaceous follicles, mainly at the level of the cephalic sphere, as well as the Meibomian glands (Ben Hadj Salah *et al.*, 2020). Demodicosis is the set of dermatological clinical manifestations related to the proliferation and dermal extension of *Demodex*, currently classified into primary and secondary forms. In this presentation, two cases of primary demodicosis were diagnosed in patients with rosacea as the underlying terrain. Indeed, *Demodex* mites have been incriminated as the cause of chronic inflammatory rashes of the skin among which rosacea - as in our two cases - remains

the most common (Elston and Elston, 2014). Apart from rosacea, contributing factors to the proliferation of *Demodex* mites included other facial dermatoses such as acne vulgaris, seborrheic and perioral dermatitis, chronic blepharitis (Aktaş Karabay and Aksu Çerman, 2020; Elston and Elston, 2014; Fromstein *et al.*, 2018), otitis externa (Elston and Elston, 2014), allergic rhinitis (Arlı *et al.*, 2019), and ocular discomfort including chalazion (Huang *et al.*, 2022; Kheirkhah *et al.*, 2007; Rabensteiner *et al.*, 2019), as well as the development of innate or acquired immunosuppression including AIDS, hematologic malignancies, and diabetes mellitus (Arlı *et al.*, 2019; Kulac *et al.*, 2008). Thus, we note that in addition to rosacea, our two reported cases were also

associated with other factors among those just mentioned, recurrent chalazion for the first case, and allergic rhinitis for case 2, respectively. Perhaps these last two factors would be consequences of the proliferation of *Demodex* rather than contributing factors (Yam *et al.*, 2013).

As explained above, rosacea being more evident on light skin (as in our two cases compared to the black complexion more common in Senegal), is much less evoked in patients with darker skin in whom it is probably underdiagnosed. Consequently, the research of *Demodex* mites, especially mentioned in this context, is very little requested in our laboratories. Moreover, these two cases described in this present work, plus two other requests from the same dermatologist and a case of an incidental finding in a patient with *tinea faciei* (unpublished data) constitute the only cases diagnosed. It should be noted that one of these cases came from another well-funded laboratory that had asked us to identify this parasite.

Diagnostic methods for the detection of *Demodex* mites are not only available but also do not require sophisticated devices. However, they are often traumatic and do not guarantee the absolute reliability of test results (Kubanov *et al.*, 2019). In this case series, DME was performed with KOH mount. This technique is the classical one and permits the visualization of the vermiform parasite 300 µm long, with four pairs of legs and a striated abdomen (Arli *et al.*, 2019). Unlike cases of blepharitis, a parasite count does not seem necessary. Thus, the question of how many mites represent an infestation remains open and further research seems necessary in this area (Chen and Plewig, 2014; Fromstein *et al.*, 2018). Moreover, the specific density of *Demodex* mites should not be a determinant, because most of these mites are located deep in the hair follicles, and only a part of them can leave the hair follicles and walk around on the skin surface (Paichitrojjana, 2022). This could give rise to false negative results

regarding the measurement of *Demodex* mites. Other diagnostic methods detecting *Demodex* are used such as dermoscopy and *in vivo* confocal microscopy examination. However, this later technique is mainly used for direct visualization of *Demodex* in eyelashes and hair follicles (Ben Hadj Salah *et al.*, 2020).

Demodicosis is adequately treated with topical and/or systemic acaricides/arachnicides (Chen and Plewig, 2014). In the present study, systemic treatment with ivermectin and doxycycline was associated with local treatment with metronidazole. Ivermectin is the treatment of choice for demodicosis with an acaricidal action. On the contrary, the treatment of rosacea with systemic tetracycline as doxycycline is controversial (Chen and Plewig, 2014). Likewise, metronidazole topicals have an effect on symptoms, but their effectiveness in reducing parasite density has not been evaluated (Ben Hadj Salah *et al.*, 2020). Ben Hadj Salah *et al.*, (Ben Hadj Salah *et al.*, 2020) citing a meta-analysis by Navel *et al.*, (Navel *et al.*, 2019) conclude that no systemic treatment is superior to the most effective topical treatments while a systematic review by Jacob *et al.*, (Jacob *et al.*, 2019) ends that other studies comparing these treatments to each other would provide additional insight into the comparative efficacy and safety for the treatment of inflammatory skin conditions associated with *Demodex*.

#### **Ethics Approval and Consent To Participate:**

Ethics approval was “Not applicable”. However, the documentation of the cases was conducted according to the guidelines of the Declaration of Helsinki. Informed consent (verbal) to participate was obtained from the two patients involved in the study.

#### **Consent for Publication:**

Informed consent for publication was provided by the participants.

#### **Authors Contributions:**

Khadim Diongue was responsible for the study design; Hadi Hakim was involved in

clinical management. Khadim Diongue and Babacar Ndiaye were implicated in the acquisition of data whereas Khadim Diongue, Mamadou Alpha Diallo, Babacar Ndiaye, Mame Cheikh Seck, Mouhamadou Ndiaye, Aïda Sadikh Badiane, and Daouda Ndiaye revised the manuscript. All the authors approved the final version of the manuscript.

#### **Acknowledgements:**

The authors are thankful to the two patients for their comprehension and cooperation as well as to Ndeye Marème Dia, a technician for her help.

**Funding:** This research received no specific grant from any funding agency in the public, commercial, or not-for-profit sectors.

**Competing Interest:** The authors declare that they are no conflicts of interest in relation to this article.

**Availability of Data And Materials:** The data used in the study are included in the article. They are also available with the corresponding author and can be shared after a kind request.

#### **REFERENCES**

- Aktaş Karabay, E., Aksu Çerman, A., 2020. *Demodex folliculorum* infestations in common facial dermatoses: acne vulgaris, rosacea, seborrheic dermatitis. *Anais Brasileiros de Dermatologia*, 95, 187–193. doi.org/10.1016/j.abd.2019.08.023
- Arlı, C., Ozsan, M., Gurkan, E., Aycan Kaya, O., Ko-Kacya, S., 2019. The incidence of *Demodex folliculorum* in the combination of allergic rhinitis and diabetes mellitus. *Iranian Journal Parasitology*, 14, 459–464. doi.org/10.18502/ijpa.v14i3.1486
- Ben Hadj Salah, W., Baudouin, C., Doan, S., Angoulvant, A., Gottlieb, J., Bénichou, J., Da Cunha, E., Eid, L., Labetoulle, M., Rousseau, A., 2020. *Demodex* and ocular surface disease. *Journal Français d'Ophthalmologie*, 43, 1069–1077. https://doi.org/10.1016/j.jfo.2020.08.002
- Chang, Y.S., Huang, Y.C., 2017. Role of *Demodex* mite infestation in rosacea: A systematic review and meta-analysis. *Journal of the American Academy of Dermatology*, 77, 441–447.e6. doi.org/10.1016/j.jaad.2017.03.040
- Chen, W., Plewig, G., 2014. Human demodicosis: Revisit and a proposed classification. *British Journal of Dermatology*, https://doi.org/10.1111/bjd.12850
- Elston, C.A., Elston, D.M., 2014. *Demodex* mites. *Clinics in Dermatology*, 32, 739–743. https://doi.org/10.1016/j.clindermatol.2014.02.012
- Fromstein, S.R., Harthan, J.S., Patel, J., Opitz, D.L., 2018. *Demodex* blepharitis: Clinical perspectives. *Clinical Optometry*, 10, 57–63. doi.org/10.2147/OPTO.S142708
- Huang, J., Guo, M.X., Xiang, D.M., Yan, L.F., Yu, Y., Han, L., Wang, J.X., Lu, X.H., 2022. The association of *demodex* infestation with pediatric chalazia. *BMC Ophthalmology*, 22, 1–6. doi.org/10.1186/s12886-022-02261-w
- Jacob, S., VanDaele, M.A., Brown, J.N., 2019. Treatment of *Demodex*-associated inflammatory skin conditions: A systematic review. *Dermatologic Therapy*, 32. https://doi.org/10.1111/dth.13103
- Kheirkhah, A., Casas, V., Li, W., Raju, V.K., Tseng, S.C.G., 2007. Corneal Manifestations of Ocular *Demodex* Infestation. *American Journal of Ophthalmology*, 143, 743–750. doi.org/10.1016/j.ajo.2007.01.054
- Kubanov, A., Gallyamova, Y., Kravchenko, A., 2019. Clinical picture, diagnosis and treatment of rosacea, complicated by *demodex* mites. *Dermatology Reports*, 11, 12–18. https://doi.org/10.4081/dr.2019.7675
- Kulac, M., Ciftci, I.H., Karaca, S.,

- Cetinkaya, Z., 2008. Clinical importance of Demodex folliculorum in patients receiving phototherapy. *International Journal of Dermatology*, 47, 72–77. <https://doi.org/10.1111/j.1365-4632.2007.03336.x>
- Navel, V., Mulliez, A., Benoist d’Azy, C., Baker, J.S., Malecaze, J., Chiambaretta, F., Dutheil, F., 2019. Efficacy of treatments for Demodex blepharitis: A systematic review and meta-analysis. *The Ocular Surface*, 17, 655–669. [doi.org/10.1016/j.jtos.2019.06.004](https://doi.org/10.1016/j.jtos.2019.06.004)
- Paichitrojjana, A., 2022. Demodex: The worst enemies are the ones that used to be friends. *Dermatology Reports*, 14. <https://doi.org/10.4081/dr.2022.9339>
- Rabensteiner, D.F., Aminfar, H., Boldin, I., Nitsche-Resch, M., Berisha, B., Schwantzer, G., Horwath-Winter, J., 2019. Demodex Mite Infestation and its Associations with Tear Film and Ocular Surface Parameters in Patients with Ocular Discomfort. *American Journal of Ophthalmology*, 204, 7–12. [doi.org/10.1016/j.ajo.2019.03.007](https://doi.org/10.1016/j.ajo.2019.03.007)
- Yam, J.C.S., Tang, B.S.F., Chan, T.M., Cheng, A.C.K., 2013. Ocular demodicidosis as a risk factor of adult recurrent chalazion. *European Journal of Ophthalmology*, 24, 159–163. <https://doi.org/10.5301/ejo.5000341>